

# The challenges of otitis media

*Despite significant obstacles, otitis media can be successfully managed.*



By Jon D. Plant,  
DVM, DACVD

Contributing Author

**T**he condition of otitis media— inflammation within the tympanic bulla—presents the veterinarian with significant diagnostic and therapeutic challenges. Among other factors, diagnostic testing has limited sensitivity, and therapeutic choices are limited by concerns regarding ototoxicity. Add to that the fact that otitis media is more likely to be associated with chronicity and *Pseudomonas aeruginosa* infections, and you have a challenging case on your hands.

Otitis media is an underdiagnosed condition in Pets, reportedly occurring in association with acute otitis externa in 16 percent of dogs and with chronic otitis externa in more than 50 percent of dogs.<sup>1,2</sup> It should be a differential diagnosis when presented with a Pet with chronic or recurrent otitis externa. An infected tympanic bulla can serve as a reservoir for bacteria and yeast that can re-infect the external ear canal.

Pets with otitis media generally present with copious aural exudate, head shaking, and pain on palpation of the ear canal— signs also frequently seen with otitis externa by itself. They may also display pain when

chewing or when the mouth is opened, due to the close proximity of the temporomandibular joint and the tympanic bulla. Nerves coursing through or in close proximity to the tympanic bulla may be damaged by inflammation (See *Nerves of the middle ear*, page 43). Air-conduction hearing loss may develop due to tympanic membrane damage, sclerosis of the ossicles, and fluid, exudate or tissue filling the tympanic bulla. Otitis media may progress to otitis interna (inflammation of the inner ear), resulting in peripheral vestibular disease and deafness.

## Pathogenesis

In dogs, otitis media most often develops as a sequela to otitis externa. The thin tympanic membrane may become porous or perforate due to infection, inflammation or foreign bodies. Unlike the external ear canal, the tympanic bulla is lined by a respiratory epithelium. Inflammation results in an increased production of mucus. In dogs, *Pseudomonas aeruginosa* and *Staphylococcus intermedius* are the most common middle ear isolates.<sup>2</sup> Repeated, suboptimal dosing with topical or systemic antibiotics has likely led to the high occurrence of resistant organisms recovered

from dogs with otitis.<sup>3</sup> *Malassezia pachydermatis* is commonly part of a mixed infection, reflecting the high frequency with which this organism causes otitis externa.

In cats, ascending otitis media is more common, and is thought to occur secondary to upper respiratory infections. *Staphylococcus intermedius* is most often cultured from the middle ear of cats. *Cryptococcus neoformans* infections may also present with signs referable to otitis media/interna.<sup>4</sup>

The tympanic bulla may be filled with mucus, pus, inflammatory polyps, granulomatous material or mineralized material (otoliths).<sup>5,6</sup> Neurological signs may result from damage to nerves closely associated with the tympanic bulla (See *Nerves of the middle ear*) or via intracranial extension of infections.<sup>7</sup>

### Diagnosis of otitis media

The diagnosis of otitis media can be made by assessing clinical signs, the integrity of the tympanic membrane (described on this page), and with the aid of diagnostic imaging. With acute disease, radiographic changes may include loss of the horizontal canal due to swelling, and with chronic disease, linear soft tissue mineralization of the external ear. The middle ear may exhibit no change, wall lysis or thickening of the tympanic bulla as well as sclerosis or opacity within the lumen. It is often overlooked, but the inner ear is visible on quality radiographs, and sclerosis or loss of detail of the labyrinth of the inner ear may be evident. Remember, the skull is a bilaterally symmetrical organ and loss of symmetry is often a clue of disease. Computed tomography (CT) was found to be more accurate and reliable than radiography for diagnosing otitis media, but not for diagnosing mild disease, in which case both modalities were

### Nerves of the middle ear

Some of the nerves closely associated with the middle ear:

- Internal carotid nerves: provide sympathetic, postganglionic innervation to the eye and orbit. Their submucosal location in the cat make them very susceptible to damage, resulting in Horner's syndrome (enophthalmos, ptosis and miosis).
- Facial nerve: damage to the facial nerve can lead to blepharospasm and paralysis of the pinna or face.
- Tympanic branch of the glossopharyngeal nerve: carries pressure and pain sensation from the middle ear.

less accurate and reliable than for more severe disease.<sup>8</sup> Magnetic resonance imaging (MRI), when available, is better suited for imaging associated soft tissue structures or masses but CT is better for bony changes.

### Determining if the tympanic membrane is ruptured

Visual inspection of the tympanic membrane and ear canal is often sufficient to ascertain whether or not the tympanum is ruptured. Tears in the pars tensa, mucus in the horizontal ear canal, or visualization of the medial aspect of the tympanic bulla are all evidence of a ruptured or absent tympanic membrane. These changes are usually not evident until the diseased external ear canal has been lavaged. An intact tympanic membrane does not rule out otitis media, as ruptured eardrums occasionally heal in the face of ongoing infection within the tympanic bulla.

Frequently, pathological changes make it difficult to recognize the tympanic membrane. Several techniques can be employed to investigate further. All require anesthesia with an endotracheal tube in place. Using

**Figure 1: Myringotomy Incision**

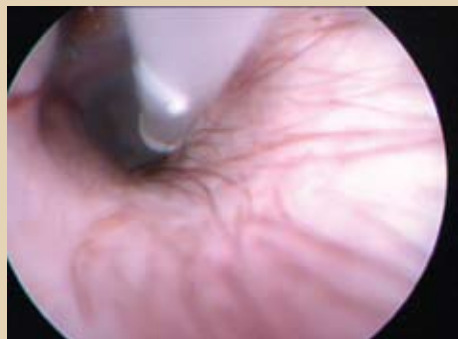

Figure courtesy of Jon Platt, DVM, DACVD

A myringotomy incision is made in the ventral-caudal pars tensa using a polypropylene (TomCat) catheter cut at a 45-degree angle with a scalpel blade. Care is taken to avoid the manubrium of the malleus. General anesthesia and good visualization are required.

the tip of a blunt polypropylene catheter, very gently palpate the tympanic membrane while visualizing it through an otoscope cone. A tympanic membrane will flex under the gentle pressure and rebound slightly; the medial aspect of the tympanic bulla will not. Positive contrast ear canalography may be used to diagnose ruptured tympanic membranes more reliably than otoscopy.<sup>9</sup> Contact a radiologist for the technique of this study. Or, with the Pet in lateral recumbency, air bubbles may be seen coming from a tear in the tympanic membrane when saline is first instilled in the ear canal.

### Healing of the TM

A perforated tympanic membrane heals in weeks to months in a normal dog. With ongoing pathological changes (infection, maceration, chronic drainage from the middle ear, excessive cerumen or accumulated hair), healing will be delayed or may not occur at all. When the only remnant

of the tympanic membrane is its attachment to the ear canal (annulus fibrocartilaginous), it is unlikely to reform. These Pets will have a permanent opening to the middle ear and require regular tympanic bulla flushing under anesthesia. Their ears should be kept dry during bathing and they should not swim. A non-ototoxic ear cleanser (e.g., TrizEDTA, DermaPet<sup>®</sup>; P1/O, GlenHaven<sup>™</sup>) should be prescribed. Because the germinal cells of the ear canal are found in the tympanic membrane, the ear canal cannot be expected to effectively self-clean (See *Management of otitis externa*, page 31).

### Therapy of otitis media

The therapy of otitis media is similar to that of otitis externa, but is complicated by several factors. The inflamed respiratory epithelium lining the tympanic bulla produces copious fluid that, if continuously draining, hinders the healing of the tympanic membrane. If the tympanic membrane is intact, myringotomy is performed to access the middle ear (*Figure 1*) and provide drainage. First, collect samples for cytology and culture. If no fluid is present, flush the bulla with 1 ml sterile saline through a polypropylene catheter, then repeatedly flush and suction the tympanic bulla with saline until clean. Bacteria isolated from the tympanic membrane are often different from ones isolated in the horizontal ear canal.<sup>2</sup> Non-ototoxic, aqueous compounded medications (e.g., dexamethasone sodium phosphate, enrofloxacin, and miconazole) can be instilled directly into the tympanic bulla. Baytril<sup>®</sup> Otic emulsion, although not approved for use with a ruptured tympanic membrane, is considered safe by many veterinary dermatologists. Ointments should not be instilled into the middle ear.

Systemic therapy for otitis externa/media

should be considered. Glucocorticoid therapy may reduce inflammation and secretions within the tympanic bulla and external ear canal. Systemic antibiotic and antifungal therapy are controversial and should be considered on a case-by-case basis based on culture and susceptibility results, disease severity, and ability of the Pet owner to treat topically. Systemic fluoroquinolones should be prescribed at the higher end of accepted dosing ranges, since they work in a concentration-dependent manner (*i.e.*, the peak concentration is more important than the time above the minimum inhibitory concentration). Subtherapeutic dosing is likely to select for bacterial resistance.

## Conclusion

Successful therapy of otitis media/externa often requires several months of continuous therapy.<sup>10</sup> The Pet should be re-examined weekly, with consideration given to repeating the middle ear lavage and infusion, if indicated based on examination findings. If available, video otoscopy allows you to capture images for future comparison and Pet owner education. Despite the obstacles and high level of Pet owner commitment required, medical management of otitis media carries a fair prognosis. Tympanic bulla lavage in combination with medical management was reported to be successful in 36/44 dogs, irrespective of their age, presence of *Pseudomonas aeruginosa*, or duration of otitis prior to referral.<sup>10</sup> Total ear canal ablation and/or bulla osteotomy should be considered when there is 1) irreversible, complete ear canal stenosis, 2) bulla osteomyelitis, 3) failure of medical therapy, or 4) complete deafness, in which case surgery may provide the Pet with a higher quality of life at a lower cost to the client than chronic medical therapy.

## Figure 2: Bulging, Intact Tympanic Membrane

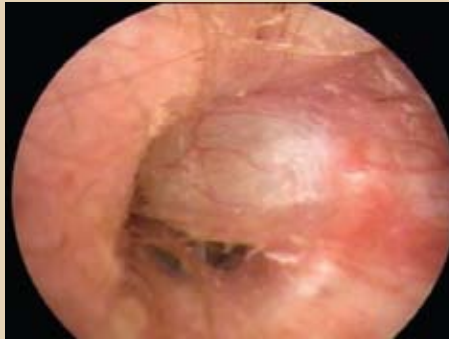


Figure courtesy of Lou Gotthelf, DVM

Primary secretory otitis media with a bulging, intact tympanic membrane.

## Primary secretory otitis media in Cavalier King Charles Spaniels

In most dogs, otitis media develops subsequent to otitis externa. However, primary secretory otitis media has been reported in Cavalier King Charles Spaniels.<sup>11</sup> Pets present with moderate to severe cervical or cranial pain or pruritus. Some may display additional neurological signs. On otoscopic examination, the external ear canal appears normal, but a bulging, intact tympanic membrane is often seen (*Figure 2*). Myringotomy reveals viscous mucus without remarkable cytological findings. After flushing the tympanic bulla, recurrence is common, necessitating repeated myringotomy procedures. Establishing continuous drainage with tympanostomy tubes placed through the tympanic membrane has recently been reported as an alternative.<sup>12</sup>

## References

1. Little CJ, Lane JG, Pearson GR. Inflammatory middle ear disease of the dog: the pathology of otitis media. *Vet Rec.* 1991;128(13):293-296.
2. Cole LK, et al. Microbial flora and antimicrobial susceptibility patterns of isolated pathogens from the horizontal ear canal and middle ear in dogs with otitis media. *J Am Vet Med Assoc.* 1998;212(4):534-538.
3. Brothers AM, Gibbs PS, Wooley RE. Development

- of resistant bacteria isolated from dogs with otitis externa or urinary tract infections after exposure to enrofloxacin in vitro. *Vet Ther.* 2002;3(4):493-500.
4. Beatty JA, et al. Peripheral vestibular disease associated with cryptococcosis in three cats. *J Feline Med Surg.* 2000;2(1):29-34.
5. Fliegner RA, Jubbs KV, Lording PM. Cholesterol granuloma associated with otitis media and destruction of the tympanic bulla in a dog. *Vet Pathol.* 2007;44(4):547-549.
6. Ziemer LS, Schwarz T, Sullivan M. Otolithiasis in three dogs. *Vet Radiol Ultrasound.* 2003;44(1):28-31.
7. Sturges BK, et al. Clinical signs, magnetic resonance imaging features, and outcome after surgical and medical treatment of otogenic intracranial infection in 11 cats and 4 dogs. *J Vet Intern Med.* 2006;20(3):648-656.
8. Rohleder JJ, et al. Comparative performance of radiography and computed tomography in the diagnosis of middle ear disease in 31 dogs. *Vet Radiol Ultrasound.* 2006;47(1):45-52.
9. Trower ND, et al. Evaluation of the canine tympanic membrane by positive contrast ear canalography. *Vet Rec.* 1998;142(4):78-81.
10. Palmeiro BS, et al. Evaluation of outcome of otitis media after lavage of the tympanic bulla and long-term antimicrobial drug treatment in dogs: 44 cases (1998-2002). *J Am Vet Med Assoc.* 2004;225(4):548-553.
11. Stern-Bertholtz W, Sjoström L, Hakanson NW. Primary secretory otitis media in the Cavalier King Charles Spaniel: a review of 61 cases. *J Small Anim Pract.* 2003;44(6):253-256.
12. Corfield GS, et al. The method of application and short term results of tympanostomy tubes for the treatment of primary secretory otitis media in three Cavalier King Charles Spaniel dogs. *Aust Vet J.* 2008;86(3):88-94.

**Jon Plant, DVM, DACVD**, graduated from Oregon State University (OSU) in 1988 and was board-certified in dermatology in 1991. Dr. Plant owned a dermatology referral practice in Marina del Rey, Calif. He then taught at OSU for three years. He joined Banfield in 2008 as a medical specialist in dermatology. He and his wife, Kara, have one daughter, two dogs and two cats.